




JETROMI

Journal of Endocrinology, Tropical Medicine, and Infectious Disease



Graves' Disease and Subdural Empyema Due to Pansinusitis: Case Report

*Roni Ananda Perwira Harahap**, *Melati Silvanni*

Endocrinology and Metabolism Division, Department of Internal Medicine, Faculty of Medicine, Universitas Sumatera Utara, Medan

ABSTRACT

Background: Graves' disease is an autoimmune disease that primarily affects the thyroid gland. It may also affect multiple other organs including eyes and skin. Brain abscess and subdural empyema are serious infections that can stem from chronic suppurative diseases, congenital cardiomyopathy, consequences of head injury, or neurosurgical intervention, but the most frequently from chronic sinusitis or otitis.

Case Presentation: A woman, age 22 years old, unmarried, came to the hospital with the main complaint of persistent headaches. Headache since 2 weeks ago along with fever that disappears arises without seizures. There is a lump in the neck for 3 years, and it has grown larger measuring 1x3 cm, immobile and supple. Nausea, vomiting, and decreased appetite are found. Thyroid function test FT4 7.52 (0.93-1.7) ng/dL and TSH 0.01 (0.270-4.20) mIU/L. Chest X-ray: Dextrocardia and Cardiomegaly; MSCT Scan Head/Brain: conclusion: Pansinusitis and Right & Left Mastoiditis; Ultrasound: thyroid: bilateral diffuse struma. MRI of the BRAIN with IV contrast: illustrating the subdural empyema. Treatment: Meropenem injection 2 g/24 hours, Dexamethasone injection 5mg/8 hours, Amitriptyline 2x12.5 mg, Thiamazole 1 x 20 mg, Propranolol 2 x 10 mg, PCT 3x1000 mg with pain scale monitoring.

Conclusion: After being treated at the hospital for 8 days, complaints of headache began to decrease, and if the general condition was stable, the patient would be planned for a craniotomy with evacuation of an abscess in the brain.

Keywords: Case report, Graves' Disease, Pansinusitis, Subdural Empyema

ABSTRAK

Latar Belakang: Penyakit Graves' adalah penyakit autoimun yang terutama mempengaruhi kelenjar tiroid. Hal ini juga dapat mempengaruhi beberapa organ lain termasuk mata dan kulit. Abses otak dan empiema subdural adalah infeksi serius yang dapat berasal dari penyakit supuratif kronis, kardiomiopati kongenital, konsekuensi cedera kepala, atau intervensi bedah saraf, tetapi yang paling sering dari sinusitis kronis atau otitis.

*Corresponding author at: Endocrinology and Metabolism Division, Department of Internal Medicine, Faculty of Medicine, Universitas Sumatera Utara, Medan

E-mail address: ronianandaperwira@gmail.com

Presentasi Kasus: Seorang wanita, usia 22 tahun, belum menikah, datang ke rumah sakit dengan keluhan utama sakit kepala terus-menerus. Sakit kepala sejak 2 minggu lalu bersamaan dengan demam yang hilang timbul tanpa kejang. Ada benjolan di leher selama 3 tahun, dan telah tumbuh lebih besar berukuran 1x3 cm, tidak bergerak dan lentur. Mual, muntah, dan nafsu makan menurun ditemukan. Tes fungsi tiroid FT4 7,52 (0,93-1,7) ng/dL dan TSH 0,01 (0,270-4,20) mIU/L. Rontgen dada: Dextrocardia dan Kardiomegali; MSCT Scan Kepala / Otak: kesimpulan: Pansinusitis dan Mastoiditis Kanan & Kiri; USG: tiroid: struma difus bilateral. MRI OTAK dengan kontras IV: menggambarkan empiema subdural. Pengobatan: Meropenem injeksi 2 g/24 jam, Dexamethasone injeksi 5mg/8 jam, Amitriptyline 2x12.5 mg, Thiamazole 1 x 20 mg, Propranolol 2 x 10 mg, PCT 3x1000 mg dengan pemantauan skala nyeri.

Kesimpulan: Setelah dirawat di rumah sakit selama 8 hari, keluhan sakit kepala mulai berkurang, dan jika kondisi umum stabil, pasien akan direncanakan untuk kraniotomi dengan evakuasi abses di otak.

Kata kunci: Laporan kasus, Penyakit Graves, Pansinusitis, Empiema Subdural

Received 06 July 2023 | Revised 24 July 2023 | Accepted 25 July 2023

1 Introduction

Graves' disease is an autoimmune disease that primarily affects the thyroid gland. It may also affect multiple other organs including eyes and skin. It is the most common cause of hyperthyroidism.[1] Like all autoimmune diseases, it occurs more commonly in patients with a positive family history. It is more common in monozygotic twins than in dizygotic twins. It is precipitated by environmental factors like stress, smoking, infection, iodine exposure, and postpartum, as well as after highly active antiretroviral therapy (HAART) due to immune reconstitution.(Hussain et al., 2017)

Subdural empyema is a suppurative infection that has no anatomic barrier to spread all over the brain convexity and into interhemispheric fissure, unlike brain abscess which is surrounded by tissue reaction, fibrin, and collagen capsule formation. (Mark S. Greenberg, 2019) Brain abscess and subdural empyema are serious infections that can stem from chronic suppurative diseases, congenital cardiomyopathy, consequences of head injury, or neurosurgical intervention, but the most frequently from chronic sinusitis or otitis. (Carpenter et al., 2007)

2 Case Presentation

A woman, age 22 years old, unmarried, came to the hospital with the main complaint of persistent headaches. Headache since 2 weeks ago along with fever that disappears arises without seizures. There is a lump in the neck for 3 years, and it has grown larger measuring 1x3 cm, immobile and supple. Nausea, vomiting, and decreased appetite are found.

History of use of drugs Tiamazole 1x10 mg and Propranolol 10 mg (for 1 year), and Paracetamol 500 mg.

Based on physical examination: sensorium conscious, underweight, no exophthalmos, struma diffuse Grade I-II, and VAS score: 3-4.

Laboratory results: routine hematology: microcytic hypochromic anemia; hyponatremia; Anti HCV, HbsAg, Anti HIV: nonreactive. Thyroid fungi test **FT4 7.52 (0.93-1.7) ng/dL** and **TSH 0.01 (0.270-4.20) mIU/L**; Ca 7,91 (8,8-10) mg/dl; fasting plasma glucose 133 mg/dL; postprandial glucose 238 mg/dL; Leukocytes 28,730 cells / μ L; platelets 382,000 cells/ μ L. ECG: Sine rhythm, Rate 112 time/min, regular, Axis: LAD, P Duration 0.08 s, PR interval 0.16 s, pathological Q(-) QRS complex 0.08 s, ST-T changes (-), T inverted(-) in V1-V4, LVH (-), RVH (-), RBBB (-), LBBB(-); conclusion: Normal sinus rhythm

Further examination: Chest X-ray: Dextrocardia and Cardiomegaly (Fig. 1). MSCT Scan Head/Brain: conclusion: No significant intracranial abnormalities appear. **Pansinusitis and Right & Left Mastoiditis** (Figure 2). Ultrasound: thyroid: **bilateral diffuse struma**. MRI of the BRAIN with IV contrast: conclusion: Crescent-shaped lesions in the left fronto-temporo-parietal region (Vol=39cc), falx, and partially cross the midline to the right frontal region, **illustrating the subdural empyema**. Post-contrast IV hyperintensities in the juxtacortical in the left frontal region and thickening of the bilateral cerebral cortex, as described by meningitis. (Fig.3). Working **Diagnosis:** Graves' Disease + Subdural Empyema caused Pansinusitis + Dextrocardia.

Treatment givens are Inj. Meropenem 2 g/24 hours, Thiamazole 1 x 20 mg, Propranolol 2 x 10 mg, Inj. Dexamethasone 5mg/8 hours , Inj. Ketorolac 1 amp/ 8 hours, Amitriptyline 2x12.5mg, PCT 3x1000 mg with pain scale monitoring

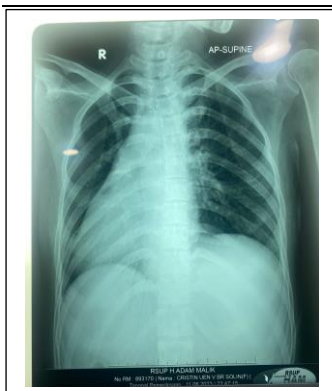

Figure 1 Chest X-ray:
Dextrocardia

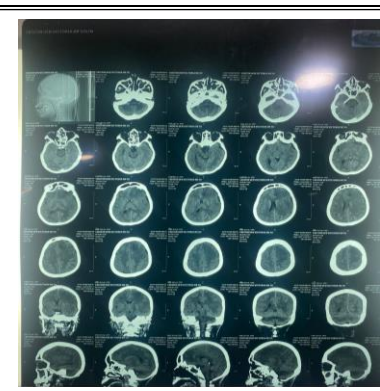


Figure 2 MSCT Scan
Head / Brain

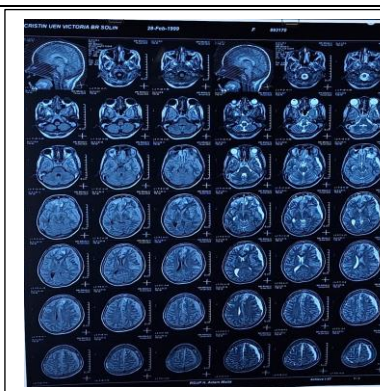


Figure 3 MRI BRAIN
with IV contrast

3 Discussion

Cerebral venous sinus thrombosis (CVT) is often categorized as a distinct subgroup of cerebrovascular disease, showing an estimated incidence of 0.5–1% of all kinds of strokes in the general population.[2] CVT is associated with various conditions that result in a hypercoagulable state. Hyperthyroidism is a predisposing factor in approximately 1.7% of patients with CVT.[3]. High levels of thyroid hormones increase blood levels of coagulation factors and inhibit fibrinolysis. Notably, increased levels of fibrinogen, von Willebrand factor, coagulation factors VIII, IX, and X, and plasminogen activator inhibitor-1 shorten the activated partial thromboplastin time and prolong the clot lysis time.[4] The combined effects of hyperthyroidism on procoagulant and fibrinolytic activity increase the risk of venous thrombosis. Pansinusitis is the most common source of suppurative intracranial and intraorbital infections.[5] Among the most common intracranial complications, we distinguish subdural empyema, epidural abscess, intracerebral abscess, meningitis, cavernous sinus thrombosis, and thrombosis of other dural sinuses.[6] It favors the male population with a male/female ratio of 3:1 and it is mostly associated with sinusitis.[7] There are three pathways for pathogens to spread and enter into brain tissue, namely contiguous, and hematogenous spread, and through unknown mechanisms.[8] Intracranial suppurative but loculated collection is mainly caused by streptococcus species.[8] Complaints related to increased intracranial pressure, meningeal irritation, and signs of cerebritis are the most frequent symptoms.[9] The prognosis and outcome have changed owing to the introduction of anti-biotherapy, improvement in microbiological identification techniques, and most importantly technological development. Magnetic resonance imaging (MRI) is a gold standard,[10] but its combined use with a diffusion-weighted image (DWI) sufficiently differentiates brain abscess from other intracranial loculated lesions. Only in a quarter of patients pathogen can be identified from blood cultures and cerebrospinal fluid.[11] Management of intracranial suppurative complication consists of antimicrobial therapy and complete surgical evacuation and lavage of purulent material.[12]

4 Conclusion

We presented one patient who developed Graves' disease, presenting headache continuously, with Subdural Empyema caused by Pansinusitis with Dextrocardia. These findings suggest Graves' disease can aggravate the infection from Pansinusitis to Subdural Empyema. If the genetic disorder Dextrocardia worsens this condition, further research needs. After being treated at the hospital for 8 days, complaints of headache began to decrease, and if the general condition was stable, the patient would be planned for a craniotomy with evacuation of an abscess in the brain.

REFERENCES

- [1]. Wémeau J Louis, Klein M, Sadoul JL, Briet C, Vélayoudom-Céphise FL. Graves' disease: Introduction, epidemiology, endogenous and environmental pathogenic factors. *Ann Endocrinol (Paris)*. 2018 Dec;79(6):599–607.
- [2]. Einhaupl K, Bousser MG, de Bruijn SFTM, Ferro JM, Martinelli I, Masuhr F, et al. EFNS guideline on the treatment of cerebral venous and sinus thrombosis. *Eur J Neurol*. 2006 Jun;13(6):553–9.
- [3]. Saposnik G, Barinagarrementeria F, Brown RD, Bushnell CD, Cucchiara B, Cushman M, et al. Diagnosis and Management of Cerebral Venous Thrombosis. *Stroke*. 2011 Apr;42(4):1158–92.
- [4]. Squizzato A, Romualdi E, Büller HR, Gerdes VEA. Thyroid Dysfunction and Effects on Coagulation and Fibrinolysis: A Systematic Review. *J Clin Endocrinol Metab*. 2007 Jul 1;92(7):2415–20.
- [5]. Osborn MK, Steinberg JP. Subdural empyema and other suppurative complications of paranasal sinusitis. *Lancet Infect Dis*. 2007 Jan;7(1):62–7.
- [6]. Jones NS, Walker JL, Bassi S, Jones T, Punt J. The Intracranial Complications of Rhinosinusitis: Can They Be Prevented? *Laryngoscope*. 2002 Jan;112(1):59–63.
- [7]. Dill SR, Cobbs CG, McDonald CK. Subdural Empyema: Analysis of 32 Cases and Review. *Clinical Infectious Diseases*. 1995 Feb 1;20(2):372–86.
- [8]. Brouwer MC, Coutinho JM, van de Beek D. Clinical characteristics and outcome of brain abscess: Systematic review and meta-analysis. *Neurology*. 2014 Mar 4;82(9):806–13.
- [9]. Tsai Y u D, Chang WN, Shen CC, Lin YC, Lu CH, Liliang P o C, et al. Intracranial suppuration: a clinical comparison of subdural empyemas and epidural abscesses. *Surg Neurol*. 2003 Mar;59(3):191–6.
- [10]. Younis RT, Anand VK, Davidson B. The Role of Computed Tomography and Magnetic Resonance Imaging in Patients With Sinusitis With Complications. *Laryngoscope*. 2002 Feb;112(2):224–9.
- [11]. Brouwer MC, Tunkel AR, McKhann GM, van de Beek D. Brain Abscess. *New England Journal of Medicine*. 2014 Jul 31;371(5):447–56.
- [12]. Bok APL, Peter JC. Subdural empyema: burr holes or craniotomy? *J Neurosurg*. 1993 Apr;78(4):574–8.